



Research Article

Copy Right@ Wannapong Triampo

# Circulating Erythroblast Abnormality Associated with Systemic Pathologies May Indicate Bone Marrow Damage.

Stefan Schreier<sup>1,2,4</sup>, Prapaphan Budchart<sup>4</sup>, Suparerk Borwornpinyo<sup>4,5</sup>, Wichit Arpornwirat<sup>6</sup> and Wannapong Triampo<sup>2,3\*</sup>

<sup>1</sup>School of Bio innovation and Bio-based Product Intelligence, Faculty of Science, Mahidol University, Thailand

<sup>2</sup>Thailand Center of Excellence in Physics, Ministry of Higher Education, Science, Research and Innovation, Thailand

<sup>3</sup>Department of Physics, Faculty of Science, Mahidol University, Thailand

<sup>4</sup>Premise Biosystems Co., Ltd. Thailand

<sup>5</sup>Excellent Center for Drug Discovery, Mahidol University, Thailand

<sup>6</sup>Department of Oncology, Bangkok Hospital, Thailand

\*Corresponding author: Wannapong Triampo, Stefan Schreier, School of Bio innovation and Bio-based Product Intelligence, Faculty of Science, Mahidol University, Department of Physics Thailand Center of Excellence in Physics, Ministry of Higher Education, Science, Research and Innovation, Premise Biosystems Co., Ltd. Thailand.

To Cite This Article: Stefan Schreier, Prapaphan Budchart, Suparerk Borwornpinyo, Wichit Arpornwirat. Circulating Erythroblast Abnormality Associated with Systemic Pathologies May Indicate Bone Marrow Damage.. 2020 - 11(1). AJBSR.MS.ID.001607.

DOI: [10.34297/AJBSR.2020.11.001607](https://doi.org/10.34297/AJBSR.2020.11.001607).

Received: 📅 November 18, 2020; Published: 📅 December 08, 2020

## Abstract

**Background:** The circulating rare cell population is diverse and rich in diagnostic information. Its characterization and clinical exploitation by cell-based liquid biopsy is an ongoing research task. Bone marrow is one of the major contributors to the peripheral blood rare cell population and consequently, determines individual rare cell profiles in dependence of health status. Bone marrow damage has been associated with aggressive or late stage systemic diseases and egress of various bone marrow cells into the blood circulation. The association of quantity and heterogeneity of circulating erythroblast with bone marrow damage is of particular interest.

**Methods:** Circulating erythroblasts from healthy, non-cancer and cancer afflicted donors were enriched by CD45 depletion and analyzed by immunofluorescence microscopy.

**Results:** Reported is a new finding of aberrant and mitotic circulating erythroid-like cells that appear similar across blood donors afflicted with various systemic pathologies. Further presented is a classification of said erythroblast-like cells in 9 subcategories according to morphological differences between phenotypically similar cells.

**Conclusion:** Aberrant and mitotic bone marrow-derived rare circulating erythroid-like cells can be detected in the blood of afflicted individuals but, not in healthy donors, suggesting being caused by bone marrow damage.

**Keywords:** Circulating rare cells, Liquid biopsy, Bone marrow damage, Erythroblast, Bone cancer, Blood donors, Cytology, Dysfunctional blood barrier, Aggressive, Mitochondrial function.

**Abbreviations:** CBLB: Cell-Based Liquid Biopsy; BMD: Bone Marrow Damage; DTC: Disseminated Tumor Cells; CTC: Circulating Tumor Cell; CEB: Circulating Erythroblast Or Circulating Erythroblast-Like Cell; N/C-Ratio: Nucleus To Cytoplasm Ratio; SCLC: Small Cell Lung Cancer; H&N: Head And Neck Cancer; BMMA: Bone Marrow Micro-Metastases Assessment; RCP: Rare Cell Population

## Introduction

Advancement in cell-based liquid biopsy comprises aspects of technology and biology [1,2]. The latter was often focused on the clinical translation of biomarkers mostly comprising known phenotypically specified cell types, such as epithelial, endothelial, or mesenchymal cells Allard et al. [3,4]. A new chapter may have been opened up with the awareness of the so called Circulating Rare Cell Population (CRP) that holds potential of cell discovery as well as of the idea of comprehensive cell analysis similar to cytology [5]. The CRP includes all kinds of non-hematopoietic but also rare hematopoietic cells mainly bone marrow-derived and suggests a greater influence of bone marrow health status on individual CRP profiles. Conversely, high diagnostic potential of the CRP, for the assessment of Bone Marrow Damage (BMD) can be deduced yet still, entails learning how to reliably retrieve and interpret the diagnostic information. One of the most promising contributors to associate BMD with CRP analysis is the circulating erythroblast.

This cell type is a known part of the CRP, yet without effective use in cell-based liquid biopsy [5]. We have earlier reported the occurrence of immature erythroblasts in healthy donors and suggested the association of respective findings above baseline with underlying pathologies [5]. Based on the commonly accepted notion that most of the circulating erythroblasts in adult life originate from the bone marrow, we have developed the hypothesis that circulating erythroblast quantification in the rare cell setting is predictive of BMD. Our herein presented data support the hypothesis having tested individuals afflicted by chronic and systemic diseases that show increased levels of immature Circulating Erythroblast-Like Cells (CEB) and for the first time reported, aberrant and mitotic versions thereof. The implications of findings of aberrated mitotic cells would represent cytological evidence of BMD and be far reaching for care in systemic diseases, so for example cancer individualized distant invasion profiling. As a first step into this research, this report intends to initially present new cell findings and propose an updated classification of CEB.

## Theory of liquid biopsy-based BMD

In cancer, BMD is expected to be caused by invasion of aggressive tumor cells referred to as Disseminated Tumor Cells (DTC) that may trigger a systemic response by way of egress of bone marrow cellular components that could be associated with the CRP [5]. Consequently, BMD detection in the setting of a cancer diagnosis is predictive of aggressive distant invasive disease. Relevant circulating cell types being indicative of and highly sensitive to slightest BMD are erythroid precursors that vary in quantity and maturation state upon bone marrow imbalances [5]. Circulating erythroblast concentrations may vary in range of  $<1$  to  $2 \times 10^5$  cells per mL depending on age, lifestyle in the lower and disease severity in the higher concentration regimen, respectively. The pathological

mechanism behind erythroblast egress is not well understood. We suggest at least two pathologies at work. One is the dysregulation of erythropoiesis; another is a dysfunctional blood barrier.

We theorize that aggressive bone marrow infiltrating tumor cells change the micro-environment of the so-called erythroid islands [6] at the vascular niche by inducing hypoxic conditions and by interaction with the erythroblast committed central macrophage [7]. Hypoxia develops in growing tumors, suggesting that active/aggressive DTC may induce hypoxia in the bone marrow micro-environment as well as outstrip their ability to take up oxygen and nutrients from their environment by diffusion. Tumor induced hypoxia is associated with poor prognosis [8]. Furthermore, DTC are theorized to be in competition with erythroblasts for physical interaction with the central macrophage then changing the activation state of the central macrophage in the erythroid island most likely causing inflammatory cell recruitment, dysregulation of erythroblast proliferation and maturation and destabilization of the vascular integrity. Furthermore, erythroblast cell cycle defects may be caused by altered mitochondrial function [9].

## Methods

### Patient Cases

A non-specific selection of systemic pathologies was chosen to investigate the presence of circulating erythroblast abnormality comprising an early and late stage breast cancer sample taking liquid biopsy after surgery, before adjuvant therapy and during chemotherapy treatment, respectively. The collection further comprised an extensive stage Small Cell Lung Cancer (SCLC) patient taking a liquid biopsy during 3rd line chemotherapy therapy. Another liquid biopsy was taken from a stage 3 head and neck cancer patient during chemotherapy. Furthermore, subjectively healthy persons with known underlying pathologies included three individuals afflicted with diabetes type II, osteoporosis, and thrombocytosis, respectively. Informed consent was sought from the patient at the time of the blood draw in accordance with IRB protocol.

### Detection platform

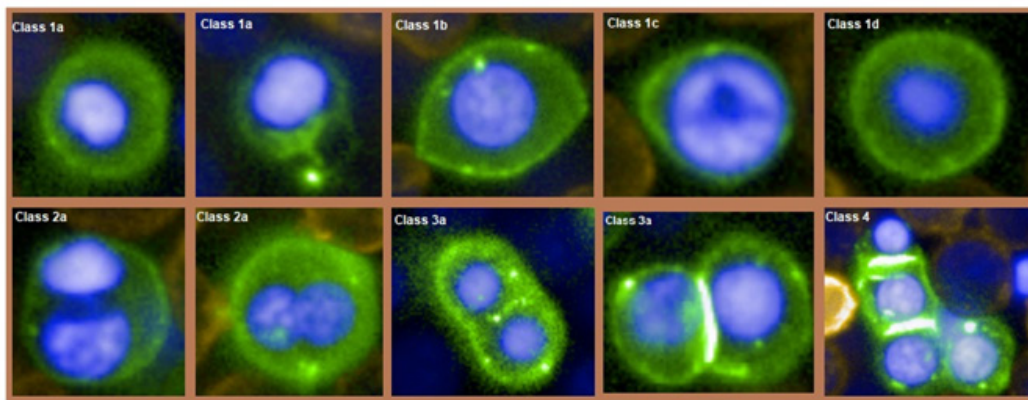
The cbLB procedure has been described in our previous publication with modifications [5]. In brief, 5mL blood taken from 17 healthy donors and 4 cancer patients was subjected to pre-enrichment by red blood cell lysis yielding highly purified nucleated cells in range of  $1.8 \times 10^7$  to  $5.5 \times 10^7$  cells. The cell suspension was further enriched by CD45 depletion assay employing an automated magnetic cell enrichment platform (Waldersbach, SanoLibio GmbH, Muenchen). The resulting cell suspension comprised carry-over leukocytes counting 3000 cells on average and all sorts of CD45 negative rare cells, amongst them CEB. To visualize their presence, the enriched cell suspension was halved and subjected to cell

membrane staining by conjugate antibodies reactive against either CD326 or CD71 and CD45 in both cases and nucleus staining by Hoechst Blue DNA stain. For analysis, the sample suspensions were loaded into two wells of a 386-well plate suitable for high resolution image recording at 40× magnification using the Operetta system (PerkinElmer) and recording a bright field channel, channels for UV, green and yellow fluorescence emission. Columbus analysis software served as screening and image analysis tool.

## Results

We have identified distinct CEB morphologies that follow the typical descriptions of erythroblasts and were phenotypically defined as CD71+/CD45-/Hoechst+ cells in the blood of cancer and non-cancer patients at relative high concentration levels and

in contrast high cell similarity in healthy donor blood at very low concentration levels, supporting the find of commonness of this phenotype and secondly suggesting high sensitivity towards bone marrow imbalances. The detected cells could be grouped into 4 main morphological distinct types which, we could be further divided into a total of 9 subtypes (Figure 1). Type 1 cells were expected and found commonly in healthy donors at low concentrations which can be grouped into small (type1a) and large (type1b) erythroblasts owing the size differences to the erythroblast maturation process [5]. Type 1a is the most abundant cell type and represents the matured circulating counterpart of otherwise bone marrow dwelling orthochromatic erythroblasts with diameters in range of 6.5µm to about 12.4µm.



**Figure 1:** Collection of CD71+/CD45-/Hoechst++ circulating erythroblast types.

Type 1a cells corresponded to the commonly described appearance with dense nuclei and a high nucleus to cytoplasm ratio (N/C-ratio). Class 1b denotes less frequent circulating immature erythroblasts with diameters greater 12.4 µm as previously described [5]. Apart from the size, immaturity is represented by a low density chromatin nuclei in diameter of about 6 µm to 10 µm and exhibiting a low N/C. Type1 could be further divided into subtypes 1c and 1d comprising megaloblasts and macro normoblasts, respectively. This cell morphology represents evidence of abnormal erythropoiesis [10] thus, being indicative of a pathological status of the bone marrow when found in the circulation. Megaloblasts show nucleocytoplasmic asynchrony and moderate to high and intracellular chromatin heterogeneity and high N/C-ratio. Macro normoblasts show no nucleocytoplasmic asynchrony, total condensation nuclei in a diameter of about 4µm to 6µm and a very low nucleus to cytoplasm ratio. Type2 CEB denotes aberrant cells of variable size and shape and are characteristic of bi-nucleation (type2a) and multi-nucleation (type2b) ascribed to asynchronous mitosis.

The types 2a and 2b may have different underlying pathologies that are being discussed in the following. Type 3 CEB denote cells

in synchronous mitosis at various stages from metaphase till cytokinesis. This type could be further divided into cells showing nuclear bridging (type3b) and those without (type3a). Types 3a events may not represent cellular aberration appearing merely in division yet represent abnormality as erythroblast proliferation supposedly takes place within the bone marrow. In contrast, type 3b cells are indicative of aberrant mitosis leading to speculate at current state, if the aberration is associated with carcinoma derived bone metastasis. Also, type 3b cells may show unequal separated nuclei with respect to shape, staining intensity, and size.

Type4 comprises cells appearing in groups of at least three round or oval normal, bi or multi nucleated cells. Type4 cells thus, represent the morphological aspect of cell clusters. These cells are seemingly in division or constitute a breakaway of aggregated erythroblasts from an erythroid island within the bone marrow. The appearance of such cell types typically reflects physical damage of the bone marrow. Consequently, metastatic growth within the bone marrow is likely Figure 1. As cornerstone, the cell types as described and illustrated could be identified across donors afflicted with varying diseases, here with head and neck cancer, lung and breast cancer and subjectively healthy donors with

known underlying conditions such as diabetes, thrombocytosis and osteoporosis (Table 1). Apart from types 1a and b, all other herein reported types were not found in the healthy cohort [5]. Also,

patients 1 and 2 afflicted with metastatic cancer showed rich CEB profiles, whereas less severe showed seemingly fewer rich profiles.

**Table 1:** Patient findings.

Patient Type	Patient Description	Type 1a	Type 1b	Type 1c	Type 1d	Type 2a	Type 2b	Type 3a	Type 3b	Type 4
1. Breast Cancer, Late Stage	Treatment-naive recurrent breast cancer & bone, liver metastasis	yes	yes	yes	yes	yes	none	yes	yes	yes
2. Breast Cancer, Early Stage	Post-surgery baseline stage 2, lymphnode negative	Yes	None	Yes	Yes	Yes	None	None	None	None
3. Small Cell Lung Cancer, Late Stage	extensive stage, brain metastasis	yes	yes	yes	none	yes	none	yes	yes	yes
4. Head and Neck, Advanced Stage	under treatment	yes	yes	none	none	none	none	yes	none	none
5. Diabetes	healthy	yes	none	none	none	yes	none	yes	none	none
6. Thrombocytosis	stable thrombocytosis, healthy	yes	yes	none	none	none	none	yes	none	none
7. Osteoporosis	Osteoporosis healthy	Yes	None	Yes	None	YES	None	None	None	None
8. Healthy	data from Schreier et al. 2018 (n=15)	yes	yes	none	none	none	none	none	none	none

## Discussion

The CRP is expected to convey a wealth of diagnostic information ascribed to the fact of lesion-associated cell egress into the blood stream or of being part of tissue repair or maintenance. It is well to say that the rarest population of cells is most decisive for, thus informative of our health. Rare cells associated with tissue repair may comprise bone marrow-derived progenitor and stem cells, those associated with lesions may comprise respective tissue-derived mature somatic cells, such as epithelial or endothelial cells. The diagnostic exploitation of such single, a few or all detectable circulating rare cells in a sample is referred to as cell-based liquid biopsy. Our investigation in that field on the circulating CD71+ phenotype has revealed a staggering variety of morphologies ascribed to erythroblast maturation, but also to pathological processes. Our data suggest conservation of that this morphological variety across pathologies and donors and contributes to the realization of the expected wealth of diagnostic information that lays in front as new cytological evidence for us to pick and correctly interpret. We would like to take the opportunity to suggest possible cytological interpretations of our findings.

The assumption lays near that CEB abnormality is directly correlated to BMD and allowing us to grade BMD based on cell quantity but also type. We further hypothesize that mere cell abnormality in the circulation is sufficient cytological evidence to diagnose a pathological condition of the bone marrow. The cell types seemingly play role in the prediction of BMD severity. CEB types 2a, 2b, 3b and 4 are cytological evidence of cell aberration suggesting moderate to severe BMD as in contrast to types 1c, d and 3a indicating abnormality in number. Our thoughts are supported by investigations of the bone marrow pathology reported aberrated

erythroblasts suggesting severe bone marrow disease, such as leukemia or hereditary anemia in case of findings of cell type 2a and 2b [11,12]. Cancer early stage detection and prevention are undoubted diagnostic goals, yet patients may firstly benefit from correct assessment of individualized cancer invasion profiles [13]. Therefore, the assessment of metastatic growth is essential part in cancer care yet, complicated in early stage and post treatment patients if not impossible in case of patients with sub-micro metastases by conventional functional imaging methods.

Also, the detection of circulating tumor cells only predicts metastases based on statistics [14,15]. In contrast, the prediction of bone marrow invasion based on conventional bone marrow biopsy provides pathological evidence of distant disease development at the individual level, yet is not routinely performed given the patient risk by the procedure and low discrimination power between dormant and active invasion. Positive findings of tumor cell dissemination at earliest stages at distant sites in the bone marrow were commonly reported from biopsies [16-18]. In fact, it was found that a large proportion of bone marrow micro-metastases positive patients (up to 70%) would not be recurrent, suggesting despite the contrary [13,19] Braun et al. 2005, Stefanoic 2016 that the detection of micro-metastasis or even of single DTC would add little valuable information to established treatment decision making as assessed by conventional histopathology.

In clinical practice, cancer treatment guidelines refrained to adopt the practice of Bone Marrow Micro Metastases Assessment (BMMA) due to obscurity in patient benefit [20]. Henceforth, the diagnostic question of BMMA and single cell invasion must be shifted from the status of distant invasion to distant aggressiveness. The detection of CEB via cell-based liquid biopsy could be a well-

suited alternative to bone marrow biopsy and moreover presenting improved stratification power between dormant or inactive and active tumor cell invasion. We can expect from our data that dormant metastases would not produce marked CEB profiles and vice versa active disease would generate detectable CEB profiles. Finally, our BMD detection platform may tap into the exciting notion of CTC/DTC guided treatment decision based on tumor evolution [18,21].

## Conclusion

The study investigated circulating erythroid nucleated cells in the blood of healthy and afflicted individuals. Bone marrow-derived erythroblasts were identified in each blood donor by positive CD71 staining and typical erythroblast morphology confirming commonness as part of the blood rare cell population. Furthermore, abnormal erythroblast-like cells as known to the pathologist from bone marrow biopsies were found only in diseased individuals in this study. This report is mainly dedicated to the new finding of aberrated and mitotic erythroblast-like cells that are so far unknown to circulate in the blood of diseased individuals foremost in cancer patients. The cell abnormality could be coarsely classified into synchronous and asynchronous mitotic, respectively and are likewise suspected to be bone marrow-derived, consequently indicating various degrees of bone marrow damage. A new cancer biomarker panel could be established in cell-based liquid biopsy when used in combination with circulating epithelial cells as a potential detection and grading platform of cancer associated bone marrow damage.

## Acknowledgments

We would like to give special thanks to Dr. Kanakorn Runglodvatana from Vajira Hospital, Bangkok for providing head and neck cancer patient blood donation.

## Ethics Approval and Consent to Participate

The study subject titles "Advancing cell-based liquid biopsy" and was approved by the Mahidol University Central IRB, Mahidol University with protocol number 2019/197.3007. All healthy donors were appointed, informed, and consented in written form. In case of the three cancer patient cases, study information was provided by the treating doctor and consent was given by the patient verbally, respectively during outpatient consultation, due to very limited visitation time.

## Competing Interest

The first author and Suparerk Borwornpinyo are shareholders of the companies involved in the development and manufacturing of cell separation technology and biomarkers as was employed in this work.

## References

1. Millner, Lori M, Mark WL, Roland V, (2013) Circulating tumor cells: a review of present methods and the need to identify heterogeneous phenotypes. *Ann Clin Lab Sci* 43(3): 295-304.
2. Panabières AC, Klaus Pantel, (2016) Clinical applications of circulating tumor cells and circulating tumor DNA as liquid biopsy. *Cancer discov* 6(5): 479-491.
3. Bhakdi, Prapat S, Ponpan T, Sebastian, Chulaluk K, et al. (2019) Accuracy of Tumour-Associated Circulating Endothelial Cells as a Screening Biomarker for Clinically Significant Prostate Cancer. *Cancers* 11(8): 1064.
4. Jones ML, Siddiqui J, Pienta KJ, Getzenberg RH, (2012) Circulating fibroblast-like cells in men with metastatic prostate cancer. *Prostate* 73(2): 176-181.
5. Schreier, Suparerk B, Rachanee U, Wannapong T, (2018) An update of circulating rare cell types in healthy adult peripheral blood: findings of immature erythroid precursors. *Ann Transl Med* 6(20): 406.
6. Bessis M, (1958) Erythroblastic island. Functional unit of the bone marrow. *Rev Hematol* 13(1): 8-11.
7. Benjamin T, Macleod, (2007) Effects of Hypoxia on Heterotypic Macrophage Interactions, *Cell Cycle*, 6(21): 2620-2624.
8. Rose, Kan V Lu, Claudia P, Patty L, Ruth G, et al. (2000) HIF1alpha Induces the Recruitment of Bone Marrow-Derived Vascular Modulatory Cells to Regulate Tumor Angiogenesis and Invasion. *Cancer Cell* 13(3): 206-220.
9. Sankaran, Stuart, Walkley, (2008) Rb intrinsically promotes erythropoiesis by coupling cell cycle exit with mitochondrial biogenesis. *Genes Dev* 22(4): 463-475.
10. Downey Hal, (1952) The megaloblast-normoblast problem: a cytologic study. *J Lab Clin Med* 39(6): 837-864.
11. Zhao, Baobing, Yang Mei, Yijie L, Xu Han, et al. (2019) Disruption of erythroid nuclear opening and histone release in myelodysplastic syndromes. *Cancer med* 8(3): 1169-1174.
12. Malcolm B, Jeremy C, Byron E, Parry TE, (1972) Congenital dyserythropoietic anemia with erythroblastic multinuclearity. *J Clin Pathol* 25(7): 561-569.
13. Pantel K, Cote RJ, Fodstad Ø (1999) Detection and clinical importance of micro metastatic disease. *J Natl Cancer Inst* 91(13): 1113-1124.
14. Klein CA, Blankenstein TJ, Schmidt KO, Petronio M, Polzer B, et al. (2002) Genetic heterogeneity of single disseminated tumor cells in minimal residual cancer. *Lancet* 360(9334): 683- 689.
15. Tharp D, Nandana S, (2019) How Prostate Cancer Cells Use Strategy Instead of Brute Force to Achieve Metastasis. *Cancers* 11(12): 1928.
16. Pantel Diel, Kaufmann, Goerner, Costa, Kaul, et al. (1992) Detection of tumor cells in bone marrow of patients with primary breast cancer: a prognostic factor for distant metastasis. *J clin Oncol* 10(10): 1534-1539.
17. Walter VP, Taran FA, Wall Wiener M, Brucker, Hartkopf, (2017) Abstract P1-01-16: Detection of disseminated tumor cells in DCIS patients impacts local recurrence. *San Antonio Breast Cancer Symposium* 78(4) Texas.
18. Banys M, Hahn M, Gruber I, Natalia K, Markus W, et al. (2014) Detection and clinical relevance of hematogenous tumor cell dissemination in patients with ductal carcinoma in situ. *Breast Cancer Res Treat* 144(3): 531-538.
19. Mignot F, Loirat D, Dureau S, Bataillon G, Caly M, et al. (2019) Disseminated tumor cells predict efficacy of regional nodal irradiation in early stage breast cancer. *Int J Radiat Oncol Biol Phys* 103(2): 389-396.
20. Harris L, Fritsche H, Mennel R, Norton L, Ravdin P, et al. (2007) American Society of Clinical Oncology 2007 update of recommendations for the use of tumor markers in breast cancer. *J clin Oncol* 25(33): 5287-5312.
21. Paluchowski B, Hartkopf, Stiegen, Janni, Solomayer, et al. (2019) Circulating and Disseminated Tumour Cells in Breast Carcinoma. *Geburtshilfe Frauenheilkd* 79(12): 1320-1327.